


Contents lists available at [ScienceDirect](https://www.elsevier.com/locate/aott)

Acta Orthopaedica et Traumatologica Turcica

journal homepage: <https://www.elsevier.com/locate/aott>

Partial quadriceps tendon transfer for revision medial patellofemoral ligament reconstruction: A new surgical technique

Joan Leal-Blanquet*, Eduard Alentorn-Geli, Raúl Torres-Claramunt, Joan Carles Monllau

Department of Orthopedic Surgery and Traumatology, Hospital del Mar i l'Esperança – Parc de Salut Mar, Universitat Autònoma de Barcelona (UAB), Barcelona, Spain

ARTICLE INFO

Article history:

Received 23 May 2015

Received in revised form

5 July 2015

Accepted 20 July 2015

Available online xxx

Keywords:

Medial patellofemoral ligament

Reconstruction

Revision surgery

Partial quadriceps tendon transfer

ABSTRACT

Medial patellofemoral ligament (MPFL) reconstruction for patellofemoral instability is a common procedure. Although MPFL reconstruction is a successful procedure in terms of return to normal life or sports, revision cases are challenging due to previous holes into the patella or implants placed in the anatomical femoral insertion site. In this technical note, the use of a partial quadriceps tendon transfer to the adductor magnus tendon is presented as a good solution for revision cases to avoid the use of implants, bone drilling, use of allografts, or two-stage surgical procedures. In addition, this procedure could be also used as a primary procedure in skeletally immature patients.

© 2017 Turkish Association of Orthopaedics and Traumatology. Publishing services by Elsevier B.V. This is an open access article under the CC BY-NC-ND license (<http://creativecommons.org/licenses/by-nc-nd/4.0/>).

Introduction

Patellofemoral instability is a common disorder in young active patients. Patellar dislocation causes injury to the medial patellofemoral ligament (MPFL), potentially leading to recurrent episodes. In cases of failed non-operatively treatment or failed primary repair of the MPFL, ligament reconstruction with or without proximal/distal realignment procedures is advisable in order to avoid new episodes of dislocation and prevent cartilage damage into the patellofemoral joint. There is a large number of surgical techniques described for MPFL reconstruction.¹ In most cases, this is a successful procedure to allow return to normal life and sports activity.²

MPFL reconstruction is usually subject to technical pitfalls. Sometimes tunnel position or orientation and isometric behavior are not adequate leading to failure. In this scenario, revision surgery has to be performed to improve patellar stability. However, revision cases may be very challenging due to previous holes into the patella or presence of implants into the anatomic femoral insertion site.

The purpose of this technical note is to report a simple surgical technique for non-anatomic MPFL reconstruction in revision cases

to avoid the use of implants for ligament fixation, unnecessary use of non-anatomic tunnels, use of allografts, or two-stage procedures.

Surgical technique

A physical examination is regularly performed before the surgical procedure to confirm inefficacy of the MPFL. The patient is positioned lying supine on the table with a padded support behind the knee to keep a flexed position of 30°. A tourniquet is placed in the proximal thigh and inflated just before the skin incision. Whenever possible, it is advisable to use the previous incisions to prevent skin complications when approaching the medial aspect of the knee. An anterior longitudinal medial parapatellar skin incision is made and the subcutaneous tissue is dissected until the extensor apparatus is exposed. This technique can also be performed with 2 small incisions in primary cases or those where no other realignment procedures are needed. In these cases, one incision is made in the anterior aspect of the knee above the quadriceps tendon and another one in the medial aspect of the knee around the adductor magnus insertion tendon. The adductor magnus tendon is then identified and dissected at the femoral insertion site. A 1 cm width of the quadriceps tendon in the medial aspect is obtained (Fig. 1a) in its complete length but only the superficial anterior half (Fig. 1b). Care must be taken to avoid detachment of the quadriceps tendon from the superior third pole of the patella. One of the important aspects to consider for this technique is the size of the graft. As

* Corresponding author.

E-mail address: jleal@parcdesalutmar.cat (J. Leal-Blanquet).

Peer review under responsibility of Turkish Association of Orthopaedics and Traumatology.

<http://dx.doi.org/10.1016/j.aott.2017.03.004>

1017-995X/© 2017 Turkish Association of Orthopaedics and Traumatology. Publishing services by Elsevier B.V. This is an open access article under the CC BY-NC-ND license (<http://creativecommons.org/licenses/by-nc-nd/4.0/>).

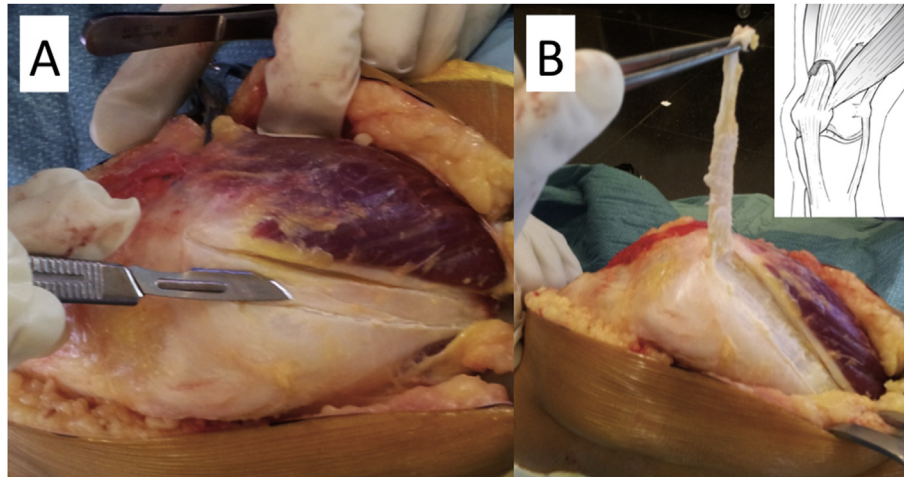


Fig. 1. Intraoperative images demonstrating autograft obtention. Panel A. Superior view of quadriceps tendon demonstrating the 1 cm width medial tendon obtention. Panel B. Superolateral view of the quadriceps tendon demonstrating the partial-thickness (superficial anterior half) autograft obtention.

other authors have described, the graft must be approximately 3 mm thick and 10 mm width.³ The major concern is the length of the graft. We recommend adding 2 cm to the distance between the quadriceps tendon insertion and the adductor magnus tendon. This will leave enough room for the quadriceps tendon to flip around the adductor magnus tendon. The length of the quadriceps tendon autograft should also be enough to allow correct isometric properties of the graft.

After graft harvesting, a passing plane is created between the vastus medialis oblique and the joint capsule until reaching the adductor magnus tendon in the medial aspect of the distal femur (Fig. 2a).⁴ The development of this plane allows adequate graft length to reach the adductor magnus tendon (Fig. 2b). It is important to avoid any perforation of the knee joint capsule when creating the passing plane for the tendon autograft. A loop is then created with the quadriceps tendon autograft around the adductor

magnus tendon (Fig. 3). It is recommended to place absorbable sutures in the attachment of the quadriceps tendon autograft into the lateral rim up to the superior third of the patella to avoid a killing corner in the tendon and prevent its rupture during or after the surgical procedure (Fig. 3). This suture also allows placing the graft in a more anatomical position. The quadriceps autograft is then sutured to itself in a termino-lateral fashion with absorbable sutures at the isometric point between 0 and 90° of knee flexion (Fig. 3). In cases of previous anatomic MPFL reconstruction, the well positioned but ineffective graft can be left in place even in cases of suboptimal functioning because this technique uses a non-anatomical attachment site (adductor magnus tendon). In cases of previous screws at the distal femur, there is no need for implant removal. Subcutaneous plane and skin are then closed and drainage is placed in order to avoid a subcutaneous haematoma. This technique can be associated with common proximal (lateral release or

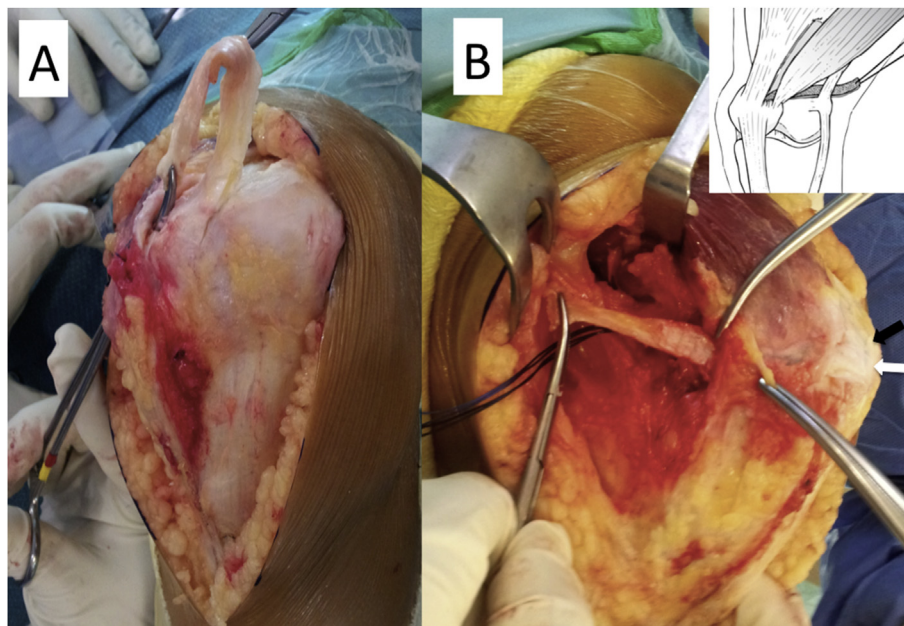


Fig. 2. Intraoperative images demonstrating autograft passage under vastus medialis obliquus. Panel A. Anterior view of the patellofemoral joint demonstrating creation of the passing plane for the autograft. Panel B. Medial view of the knee demonstrating the passage of the quadriceps autograft into the medial side. The black arrow represents the superior pole of the patella whereas the white arrow represents the origin of the quadriceps tendon autograft.

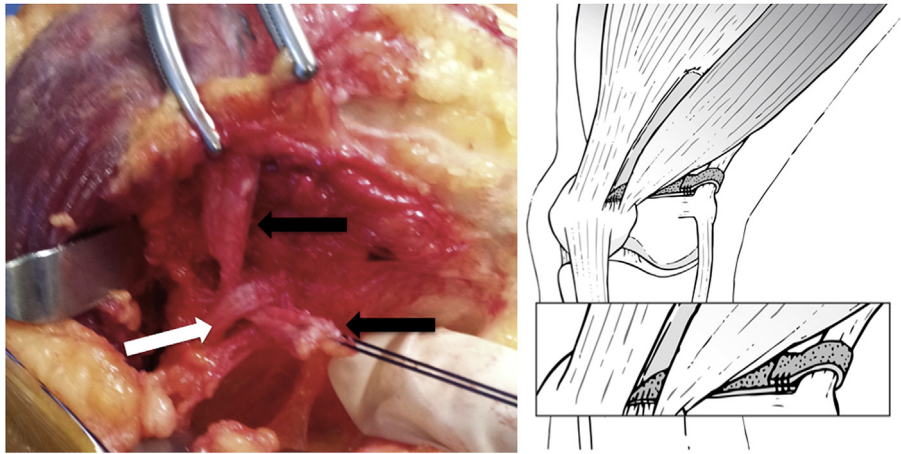


Fig. 3. Intraoperative image and drawing demonstrating the quadriceps tendon autograft (black arrows) loop around the adductor magnus tendon (white arrow).

Insall's procedure) and distal realignment (tibial tubercle osteotomy) procedures to achieve patellofemoral stability. The post-operative rehabilitation protocol can be the same as in other techniques used for MPFL reconstruction.

Preliminary data on 4 patients at a mean follow-up of 10 months demonstrate absence of pain and instability symptoms, complete recover of the pre-operative range of motion, improvements in the Kujala and Lysholm scores, and excellent satisfaction with surgery.

Discussion

The main current surgical treatment for the realignment of the extensor apparatus is still the use of "classical" realignment techniques. However, it has been observed in the last decade that the association of the reconstruction of the MPFL increases the stability of the extensor apparatus. It has been even recommended to perform isolated reconstruction of the MPFL.¹ There are many anatomic and non-anatomic reconstruction techniques described for the MPFL.^{1,5} The combination of MPFL reconstruction associated with any other proximal or distal realignment procedures is likely the treatment of choice to achieve successful results,⁶ especially in revision cases or those where an associated procedure is clearly needed. Therefore, it is recommended to design surgical techniques for MPFL reconstruction than can also be applied in combination with other procedures.

The ideal indication for the surgical technique presented in this article is the failure of previous anatomic MPFL reconstruction. The main reasons for failure of previous MPFL reconstruction are: 1) malpositioning of the reconstructed ligament; 2) lack of association of other realignment procedures when they are actually needed (increase in TT-TG distance, trochlear dysplasia, or patella alta, among others); and 3) new trauma event that ruptures of the reconstructed ligament.

Many revision cases have one or multiple holes into the patella, which increases the risk of intraoperative patellar fracture or tunnel widening if another hole is done. Tunnel widening may also occur when trying to remove a screw previously placed in the anatomic insertion site of the ligament into the patella. If hole widening occurs, a two-stage procedure must be expected. Therefore, this technique would be indicated in revision cases to avoid intraoperative patellar complications and staged procedures.

In cases of previous non-anatomic MPFL reconstruction, the most adequate approach would be to reconstruct the new ligament in the anatomic position with any of the available surgical techniques. The present surgical technique would be mainly indicated

in cases of failure of anatomic MPFL reconstruction. There are several non-anatomic MPFL reconstruction techniques described. Some of them have used either complete or partial adductor magnus tendon transfer,^{7,8} the semitendinosus tendon around the medial collateral ligament,⁹ or the quadriceps tendon.^{10,11} The use of the adductor magnus tendon transfer or the semitendinosus tendon is not recommended in cases of multiple holes in the patella from previous surgeries, as it also requires some kind of fixation into the patella. Surgical techniques using quadriceps tendon previously described have placed the tendon anatomically in the distal femur using sutures or screws through bone tunnels.^{3,10,11} Therefore, the present surgical technique has the advantage of avoiding bone tunnels and keeps a pedicle patellar vascularization in the area. Anatomical placement of the quadriceps tendon may be very challenging in cases of previous screws at the appropriate femoral insertion site. Removing screws may not be easy and may cause hole widening in the femur, which could require a two-stage procedure. The use of bone sutures or suture anchors would be an alternative, but the fixation could not be as strong as with interference screws.¹² In addition, implant collision could potentially be an issue if previous implants are not removed. Therefore, this technique would be advantageous over other non-anatomical techniques because it does not require implant removal or tunnels performed in either the patella or femur.

The use of the quadriceps tendon autograft has the advantage of keeping the native patellar insertion site, which would be related to a better biological healing.¹³ Moreover, this autograft choice would have the benefits of avoiding morbidity in other donor sites (with the additional requirement of more skin incisions). Additionally in many revision cases the use of allografts is needed, so the quadriceps autograft would be a good solution to prevent disease transmission and concerns on vitality of the graft.

Some disadvantages of this technique are: 1) non-anatomic reconstruction; 2) potential risk of increasing patellar shift/tilt or causing patellar malrotation; and 3) the autograft length may be shorter than required to maintain the correct isometry. These potential drawbacks are similar than those reported in previous studies using the quadriceps tendon graft.^{3,4,11,13–15} Malposition in patellar site can be solved anchoring the distal quadriceps tendon attachment with a good transosseous suture in the correct anatomical point. The general advantages of the surgical technique described in this article are: 1) no need of implants; 2) no need of bone drilling; 3) no need of allografts in cases of multiple previous procedures using autografts; 4) isometric tensioning can be simply achievable; 5) avoidance of two-stage procedures; and 6) easily

used in combination with distal realignment procedures. In addition, the use of an adductor sling technique as the one presented in this article can also be indicated in skeletally immature patients as a primary procedure.¹

In conclusion, the use of a partial quadriceps tendon transfer to the adductor magnus tendon is presented as a good solution for revision cases to avoid the use of implants, bone drilling, use of allografts, and two-stage surgical procedures.

References

- Sillanpaa PJ, Maenpaa HM, Arendt EA. Treatment of lateral patella dislocation in the skeletally immature athlete. *Oper Tech Sports Med.* 2010;18(2):83–92.
- Smith TO, Walker J, Russell N. Outcomes of medial patellofemoral ligament reconstruction for patellar instability: a systematic review. *Knee Surg Sports Traumatol Arthrosc.* 2007;15(11):1301–1314.
- Fink C, Veselko M, Herbort M, Hoser C. MPFL reconstruction using a quadriceps tendon graft: part 2: operative technique and short term clinical results. *Knee.* 2014;21(6):1175–1179.
- Nelitz M, Williams SR. Anatomic reconstruction of the medial patellofemoral ligament in children and adolescents using a pedicled quadriceps tendon graft. *Arthrosc Tech.* 2014;3(2):e302–e308.
- LeGrand AB, Greis PE, Dobbs RE, Burks RT. MPFL reconstruction. *Sports Med Arthrosc.* 2007;15(2):72–77.
- Koh JL, Stewart C. Patellar instability. *Clin Sports Med.* 2014;33(3):461–476.
- Avikainen VJ, Nikku RK, Seppanen-Lehmonen TK. Adductor magnus tenodesis for patellar dislocation. Technique and preliminary results. *Clin Orthop Relat Res.* 1993;297:12–16.
- Sillanpaa P, Maenpaa HM, Mattila VM, Visuri T, Pihlajamaki H. A mini-invasive adductor magnus tendon transfer technique for medial patellofemoral ligament reconstruction: a technical note. *Knee Surg Sports Traumatol Arthrosc.* 2009;17(5):508–512.
- Deie M, Ochi M, Sumen Y, Yasumoto M, Kobayashi K, Kimura H. Reconstruction of the medial patellofemoral ligament for the treatment of habitual or recurrent dislocation of the patella in children. *J Bone Jt Surg Br.* 2003;85(6):887–890.
- Macura M, Veselko M. Simultaneous reconstruction of ruptured anterior cruciate ligament and medial patellofemoral ligament with ipsilateral quadriceps grafts. *Arthroscopy.* 2010;26(9):1258–1262.
- Steensen RN, Dopirak RM, Maurus PB. A simple technique for reconstruction of the medial patellofemoral ligament using a quadriceps tendon graft. *Arthroscopy.* 2005;21(3):365–370.
- Russ SD, Tompkins M, Nuckley DJ, Macalena JA. Biomechanical comparison of patellar fixation techniques in medial patellofemoral ligament reconstruction. *Am J Sports Med.* 2015;43(1):195–199.
- Herbort M, Hoser C, Domnick C, et al. MPFL reconstruction using a quadriceps tendon graft. Part 1: biomechanical properties of quadriceps tendon MPFL reconstruction in comparison to the intact MPFL. A human cadaveric study. *Knee.* 2014;21(6):1169–1174.
- Herbort M, Hoser C, Lenschow S, et al. Biomechanical properties of a new MPFL reconstruction technique using quadriceps tendon in comparison to the intact MPFL. A human cadaveric study. *Arthroscopy.* 2013;29(10 Supplement):84–85.
- Goyal D. Medial patellofemoral ligament reconstruction: the superficial quad technique. *Am J Sports Med.* 2013;41(5):1022–1029.