


CASE REPORTS

Evaluation of the density spectral array in the Wada test: report of six cases



Susana Pacreu ^{a,*}, Esther Vilà^a, Luis Moltó^a, Rodrigo Rocamora^b,
Juan Luis Fernández-Candil^a

^a Hospital del Mar, Department of Anestesiología y Reanimación, Barcelona, Spain

^b Hospital del Mar, Department of Neurología, Barcelona, Spain

Received 28 March 2019; accepted 27 February 2021

Available online 8 April 2021

KEYWORDS

Wada test;
Epilepsy;
Amobarbital;
Alpha waves;
Density spectral
array;
Loss of consciousness

Abstract Wada test is an invasive procedure used in the preoperative evaluation for epilepsy surgery to determine language lateralization, postoperative risk of amnesia syndrome, and to assess the risk of memory deficits. It involves injection of amobarbital into internal carotid artery of the affected hemisphere followed by the healthy hemisphere to shut down brain function. We performed an observational study evaluating the density spectral array (DSA) of the bilateral bispectral index VISTA™ Monitoring System (BVMS) in 6 patients with drug-resistant epilepsy undergoing Wada test. DSA revealed the presence of bifrontal alpha waves in absence of loss of consciousness in all patients.

© 2021 Sociedade Brasileira de Anestesiologia. Published by Elsevier Editora Ltda. This is an open access article under the CC BY-NC-ND license (<http://creativecommons.org/licenses/by-nc-nd/4.0/>).

Introduction

As anesthesiologists we are interested in knowing the effect on processed EEG when an anesthetic is administered in cerebral arteries. As an epilepsy reference center we have studied this effect in the Wada test, a procedure employed to evaluate language lateralization and memory lateralization in patients affected by temporal epilepsy, and who are candidates for temporal lobe resection.¹ Our center the

Epilepsy Group of the Neurological Department uses the functional magnetic resonance imaging (fMRI), a noninvasive technique, to study the language and memory lateralization. But when the results are inconclusive, the Wada test remains the most direct method to assess the risk of verbal memory decline after surgical treatment.

The Wada test consists of an injection of amobarbital (an ultrashort acting barbiturate) through the internal carotid artery (ICA) to reach zones perfused by the middle cerebral artery (MCA) and the anterior cerebral one (ACA). One of the hemispheres is thus either totally or partially anesthetized in order to evaluate the function of the other.¹ The expected effect is to produce transient aphasia and

* Corresponding author.

E-mail: 94397@parcdesalutmar.cat (S. Pacreu).

contralateral hemiplegia once the drug is injected into the speech-dominant hemisphere.

A cerebral angiogram is always performed by transfemoral catheterization of the ICA in order to visualize the shape of intracranial vascularization and the crossflow to the contralateral hemisphere. This stage is crucial because major vascular fluctuations could influence the results of the test. In this sense, the medial temporal region and part of the hippocampus are irrigated by the anterior choroidal artery (ACdA) that usually originates from the ICA, and the posterior two thirds of the hippocampus depend on the posterior cerebral artery (PCA), a branch of the vertebrobasilar system. Patients with PCA thromboembolic disease have memory deficits frequently, although the contribution of this posterior part to the memory function is unclear.² A variation of PCA, named Fetal PCA, originating in the ICA is observed in approximately 25% of patients making hippocampus function in this part of the hemisphere totally dependent on the ICA. In this situation, the administration of the barbiturate could affect all the hippocampus in this hemisphere, and memory evaluation would totally depend on the other hemisphere.²

The bilateral bispectral index (BIS) VISTA™ Monitoring System (BVMS) includes a bifrontal sensor with four EEG channels to continuously monitor the frontal lobes of both hemispheres. This monitor shows the distribution of EEG power in relation to frequency across time with a color spectrogram named density spectral array (DSA). DSA applies Fourier's Transformation converting the EEG signal from amplitudes fluctuating in the time domain to power in the frequency domain. Changes in power of the frequency bands as delta (1 to 4 Hz), theta (4–10 Hz), alpha (8–12 Hz), and beta (> 12 Hz) can be used to quantify the brain effect of anesthetic agents. DSA also shows very low-frequency oscillations (approximately 1 Hz). In addition, the 95% spectral edge frequency (SEF 95) can be observed. SEF 95 is the frequency below which 95% of the total spectral power lies. Another variable is asymmetry (ASYM), which is processed and indicates the EEG power present in either the left or right hemispheres with respect to total EEG power (both hemispheres).³ When relative values are greater than 50% in amplitude and/or frequency, they are considered significant and correlate with neuropathological findings.

The aim of this study was to observe DSA evolution in both hemispheres after the administration of amobarbital in six patients with pharmacoresistant epilepsy and candidates for temporal lobe resection.

Material and methods

A prospective, observational study of the DSA in 6 candidates for temporal lobe resection of the epileptogenic focus in whom the Wada test had been performed. The study was approved by the Institutional Ethics Committee (2020/9448). Three women and three men were included: American Society of Anesthesiologists (ASA) physical status II/III (3/3), age 35 ± 8.9 years, weight 6.23 ± 21.75 kg, and height 168.54 ± 10.87 cm. To carry out this test the patients signed the corresponding informed consent. An anesthetist was present to monitor cardiovascular and respiratory parameters and deal with any complications that may have arisen.

Epileptic male and female individuals aged over 18 years who were eligible for surgery were included. Exclusion criteria were: hemodynamic instability (arterial hypotension) or complete auricular-ventricular blockage; moderate/severe renal insufficiency (creatinine clearance $< 60 \text{ mL}\cdot\text{min}^{-1}$); allergy/hypersensitivity to the active substance; or some of the excipients of amobarbital.

The 6 patients attended the neuroangiography area with their electrode helmets in place following the International 10–20 System and EEG measuring commenced together with the bilateral BVMS. The BVMS DSA shows a spectral range between 0.5 and 30 Hz, but for the purposes of this study changes of drug effect above 12 Hz were not evaluated. During the procedure systolic/diastolic arterial blood pressure, the electrocardiogram, and percentage oxygen saturation by pulse oximetry were monitored in all patients. A neuro-radiologist introduced a catheter from the femoral artery towards the ICA in the affected hemisphere. Once the catheter was in place the patient was asked to raise both arms, amobarbital was then administered until the arm contralateral to the injected hemisphere fell. A mean dosage of 125 mg of amobarbital was given. The language test commenced immediately, including naming objects in a picture, and memory exploration through remembering phrases and objects previously shown. Thirty minutes after finishing the test (the time required between the two injections for the hypnotic effect to disappear), the same procedure was repeated in the healthy hemisphere. The Wada test in the 6 patients lasted approximately 90 minutes, after completion they were moved to a hospital ward.

Results

Two of the 6 patients had an extensive connatal lesion in the hemisphere where the epileptogenic focus was located. The cerebral angiogram detected fetal PCA in 2 of the 6 patients. The remaining 4 presented a pharmacoresistant focus. In these 4 patients the administration of amobarbital, first in the diseased hemisphere and later in the healthy one, produced the respective contralateral brachial hemiplegia. At this moment, in patients 1, 2, 3, and 4 the BVMS showed the presence of alpha activity in consonance with low frequency oscillations in both hemispheres but none of them had amobarbital perfusion in the contralateral hemisphere. In patient 5 theta and alpha activity were observed (8 Hz), and in patient 6, who presented extensive brain damage in the left hemisphere, delta activity predominated (Fig. 1). Only the patient 5 showed amobarbital cross-perfusion because the left anterior cerebral artery irrigates part of the right territory.

During the procedure there were no cardiologic or respiratory complications and the Wada test was performed without incidents.

Discussion

The DSA provided by the BVMS allowed us to observe the baseline state of the brain and to evaluate the responses to the anesthetic procedures. The administration of amobarbital not only affected the injected hemisphere (ipsilateral)

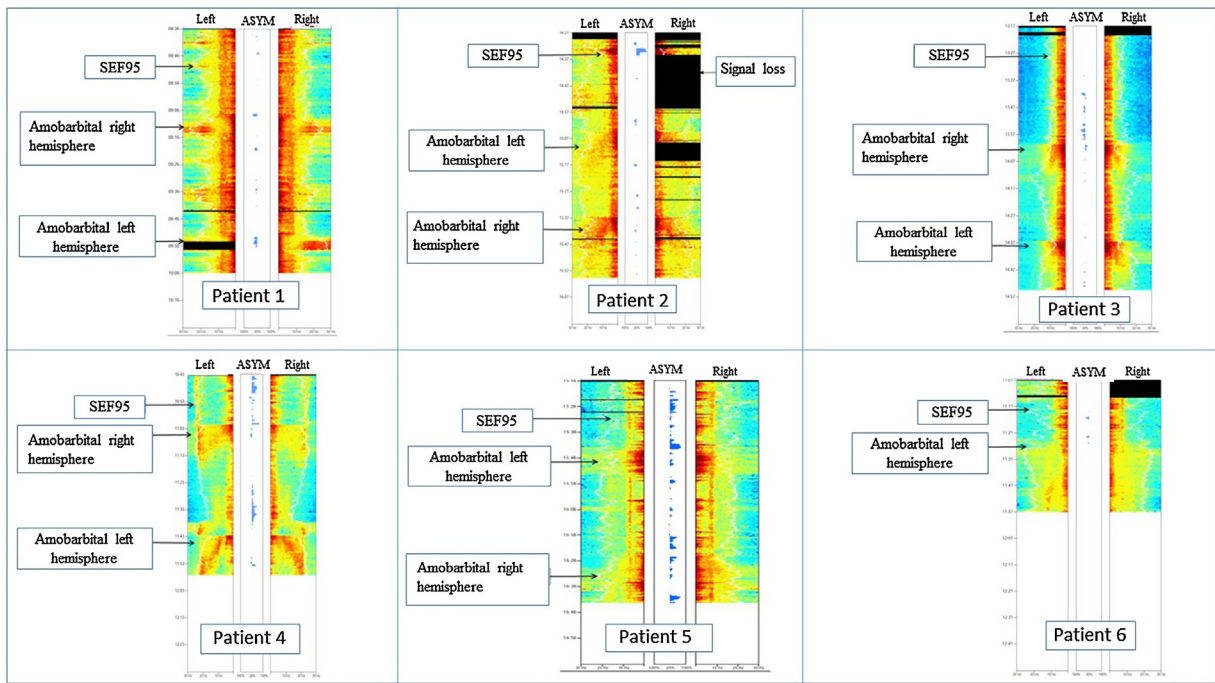


Figure 1 Density spectral array (DSA) of patients with pharmacoresistant epilepsy. Warmer colors indicate higher power, cooler colors represent lower power and black bars indicate periods of signal loss. In patients 1, 2, 3, and 4 DSA showed the presence of alpha activity and slow oscillations in both hemispheres. In patient 5, with left parieto-temporal-insular malacia/gliosis secondary to chronic ischemic lesion, DSA showed theta and alpha activity. In patient 6, with sclerosis and extense left frontal encephalomalacia injury due to connatal etiology, DSA showed delta activity.

but also had an influence on the non-anesthetized one (contralateral).

Purdon et al. have reported that during the moments prior to anesthetic induction, when the patient is still awake, gamma (25–40 Hz) and beta (13–24 Hz) waves predominate. On performing induction, alpha waves (8–12 Hz) and very low frequency oscillations (0.1–1 Hz) increase significantly. Fifteen minutes after loss of consciousness, the alpha waves concentrate in the frontal channels whilst the low-frequency ones are found in the temporal and parietal regions.⁴ This phenomenon is known as anteriorization. Studies have demonstrated that with the loss of consciousness (LOC) following the intravenous administration of propofol anteriorization appears on the power spectrum due to thalamocortical synchronization.⁴ Low frequency (delta) and alpha waves are linked to the LOC during conventional anesthetics.⁴ During the awakening from anesthetics these changes are reversed, and with consciousness the alpha and low-frequency waves disappear from the frontal channels whilst beta and gamma ones reappear.⁴ Nevertheless, it is not clear whether this phenomenon can be extrapolated to amobarbital or inhaled drugs which present a different molecular circuit.^{5,6}

In our study, the administration of amobarbital in one hemisphere led to the appearance of bifrontal alpha and delta waves on the power spectrum which was not associated with LOC. Moreover, the DSA showed an effect of the same drug on the anterior and middle cerebral arteries.

Douw et al suggested that the unilateral injection of barbiturates could produce bilateral changes in

synchronization.⁷ According to these authors, the arterial administration of amobarbital could lead to an alteration in the functional connectivity of both the injected hemisphere and the contralateral one. It could result in EEG slowing (a greater proportion of slow waves) in both hemispheres. Patients 1, 2, 3, and 4 depict the alpha waves in both hemispheres when amobarbital has been intravenously administered. During the first seconds of the injection the barbiturate could pass to the contralateral hemisphere through the Circle of Willis, nevertheless, the spectrogram pattern appears to be fundamentally produced by a transitory functional disconnection of the ipsilateral hemisphere.⁷ Such occurrence has been well-established when lesions appear in the area as in the patients 5 and 6.

The results should be cautiously interpreted because of the limitations of the technique and study. There is evidence of amobarbital anesthetics failing in patients taking carbonic anhydrase inhibitors and certain anti-epileptic medications (Topiramate and Zonisamide).⁸ In our study only one patient took Topiramate and the Wada test was considered successful. Another limitation is that BVMS only permits the evaluation of the frontal electrodes and there is a delay in processing the data. In our study only patient 2 was affected by frontal epilepsy.

In summary, the Wada test represents an opportunity to investigate the effect of a hypnotic directly administered to the brain. The DSA obtained from the BVMS was able to demonstrate drug-induced effects (for instance, bifrontal alpha and delta waves) in absence of loss of consciousness in patients undergoing the Wada test.

Conflicts of interest

The authors declare no conflicts of interest.

References

1. Abou-Khalil B. An update on determination of language dominance in screening for epilepsy surgery: the Wada test and newer non-invasive alternatives. *Epilepsia*. 2007;48:442–55.
2. Zijlmans M, Huibers CJ, Huiskamp GJ, et al. The contribution of posterior circulation to memory function during the intracarotid amobarbital procedure. *J Neurol*. 2012;259:1632–8.
3. Purdon PL, Sampson A, Pavone KJ, et al. Clinical Electroencephalography for anesthesiologists. *Anesthesiology*. 2015;123:1–24.
4. Purdon P, Pierce E, Mukamel E, et al. Electroencephalogram signatures of loss and recovery of consciousness from propofol. *Proc Natl Acad Sci U S A*. 2013;110:E1142–51.
5. Löscher W, Rogawski MA. How theories evolved concerning the mechanism of action of barbiturates. *Epilepsia*. 2012;53:12–25.
6. Blain-Moraes S, Tarnal V, Vanini G, et al. Neurophysiological correlates of sevoflurane-induced unconsciousness. *Anesthesiology*. 2015;122:307–16.
7. Douw L, Baayen JC, Klein M, et al. Functional connectivity in the brain before and during intra-arterial amobarbital injection (Wada test). *Neuroimage*. 2009;46:584–8.
8. Bookheimer S, Schrader LM, Raush R, et al. Reduced anesthetization during the intracarotid amobarbital (Wada) test in patients taking carbonic anhydrase-inhibiting medications. *Epilepsia*. 2005;46:236–43.