



Online versus offline spatiotemporal image correlation (STIC) M-mode for the evaluation of cardiac longitudinal annular displacement in fetal growth restriction

Jozien C. Tanis, Nuruddin Mohammed, Mar Bennasar, Josep Maria Martinez, Bart Bijmens, Fatima Crispi & Eduard Gratacos

To cite this article: Jozien C. Tanis, Nuruddin Mohammed, Mar Bennasar, Josep Maria Martinez, Bart Bijmens, Fatima Crispi & Eduard Gratacos (2018) Online versus offline spatiotemporal image correlation (STIC) M-mode for the evaluation of cardiac longitudinal annular displacement in fetal growth restriction, The Journal of Maternal-Fetal & Neonatal Medicine, 31:14, 1845-1850, DOI: [10.1080/14767058.2017.1330408](https://doi.org/10.1080/14767058.2017.1330408)

To link to this article: <https://doi.org/10.1080/14767058.2017.1330408>



© 2017 The Author(s). Published by Informa UK Limited, trading as Taylor & Francis Group.



[View supplementary material](#)



Published online: 31 May 2017.



[Submit your article to this journal](#)



Article views: 604



[View related articles](#)



[View Crossmark data](#)



Citing articles: 4 [View citing articles](#)

ORIGINAL ARTICLE



Online versus offline spatiotemporal image correlation (STIC) M-mode for the evaluation of cardiac longitudinal annular displacement in fetal growth restriction

Jozien C. Tanis^{a,b,c}, Nuruddin Mohammed^{a,b}, Mar Bennasar^{a,b}, Josep Maria Martinez^{a,b}, Bart Bijlens^d, Fatima Crispi^{a,b} and Eduard Gratacos^{a,b}

^aBCNatal – Barcelona Center for Maternal-Fetal and Neonatal Medicine (Hospital Clínic and Hospital Sant Joan de Deu), Institut Clínic de Ginecologia, Obstetrícia i Neonatologia, Institut d'Investigacions Biomèdiques August Pi i Sunyer, Universitat de Barcelona, Barcelona, Spain; ^bCentre for Biomedical Research on Rare Diseases (CIBER-ER), Barcelona, Spain; ^cDepartment of Obstetrics and Gynecology, Fetal Medicine Unit, University Medical Center Groningen, University of Groningen, Groningen, The Netherlands; ^dICREA, Universitat Pompeu Fabra, Barcelona, Spain

ABSTRACT

Purpose: Our first aim was to compare online M-mode with offline spatiotemporal image correlation (STIC) M-mode for assessing longitudinal annular displacement (LAD) in growth-restricted fetuses (FGR). Our second aim was to compare LAD measures of FGR cases with controls.

Materials and methods: Prospective study including 40 FGR cases (defined estimated fetal weight and birth weight <10th centile) and 72 normally grown fetuses matched to cases by gestational age at scan. LAD was measured with online M-mode and offline STIC M-mode at the left and right ventricular free walls and septum in all fetuses.

Results: FGR cases had a significant decrease in LAD by STIC in all sites as compared to controls (e.g. right LAD in FGR mean 6.7 mm (SD 1.2) versus controls 7.2 mm (1.2), $p = .033$). There was a non-significant trend for lower values in FGR when using online M-mode (e.g. right LAD in FGR 6.9 mm (1.5) versus controls 7.4 mm (1.5), $p = .084$).

Conclusions: STIC M-mode seems a better method than online M-mode for detecting subtle changes in myocardial motion. STIC presents more precise results and allows an ideal placement of the M-mode arrow. These results confirm previous data suggesting decreased longitudinal motion in FGR.

ARTICLE HISTORY

Received 23 March 2017

Revised 1 May 2017

Accepted 10 May 2017

KEYWORDS



FGR; longitudinal annular displacement; M-mode; STIC


Introduction

Evaluation of cardiac function is increasingly used for the characterization and understanding of fetal diseases. Fetal cardiac function assessment is technically challenging, and the development of reproducible methods is critical to allow comparability among studies. Longitudinal annular displacement (LAD) is the most commonly used parameter, because it is an easy and reproducible method to measure myocardial motion [1–10]. LAD is normally evaluated by online motion mode (M-mode) at the free ventricular walls and the interventricular septum. However, online M-mode has a few disadvantages. A main limitation of M-mode is the difficulty of obtaining a perfect alignment of the M-mode line with the ventricular walls at an angle close to 0°, particularly in the left free wall.

This might introduce some bias in the detection of mild changes in ventricular motion, both in prenatal and postnatal evaluations. In addition, obtaining a perfect 4-chamber view, i.e. with similarly sized left/right chambers and atrioventricular valves, for measuring LAD in the optimal position is often challenging.

Spatiotemporal image correlation (STIC) provides an offline method for four-dimensional (4D) analysis of the fetal heart, which was first demonstrated by Messing et al [6,11–13]. STIC is also dependent on the position of the fetal heart, however, it seems to have some advantages over online M-mode. STIC allows placing the M-mode arrow in any preferred position to measure LAD and it can also rotate the volume for obtaining an optimal four-chamber view. In this study, we hypothesized that LAD measured with STIC could

CONTACT Jozien C. Tanis  j.c.tanis@umcg.nl  Division of Neonatology, Beatrix Children's Hospital, University Medical Center Groningen, University of Groningen, Hanzeplein 1, CA51, 9713 GZ Groningen, The Netherlands

 Supplemental data for this article can be accessed [here](#).

© 2017 The Author(s). Published by Informa UK Limited, trading as Taylor & Francis Group.

This is an Open Access article distributed under the terms of the Creative Commons Attribution-NonCommercial-NoDerivatives License (<http://creativecommons.org/licenses/by-nc-nd/4.0/>), which permits non-commercial re-use, distribution, and reproduction in any medium, provided the original work is properly cited, and is not altered, transformed, or built upon in any way.

be a better method to detect differences in fetal diseases as compared to online M-mode. To test this hypothesis, we used fetal growth restriction (FGR) as disease model. In FGR, the heart is a central organ in the adaptive mechanisms to placental insufficiency [14,15] displaying profound structural and functional changes prenatally [16], which persist into childhood [17,18]. Briefly, FGR is associated with cardiac remodeling to more globular hearts, with impaired relaxation and decreased longitudinal myocardial motion as measured by online M-mode [19,20].

Our first aim was to perform a prospective study to compare LAD measures using online conventional M-mode versus offline STIC M-mode in 40 FGR cases and 72 normally grown fetuses. Our second aim was to compare LAD measures of FGR cases with controls.

Methods

Study design and population

The study design was a prospective cohort study including 40 case subjects with FGR and 72 control subjects. The source population consisted of women with a singleton pregnancy attending the Department of Maternal-Fetal Medicine at Hospital Clinic in Barcelona from January 2013 to October 2014. Cases and controls were included in consecutive order. FGR was defined by both estimated fetal weight (EFW) below the 10th centile and birth weight below the 10th centile, according to local standards [21]. Clinical follow-up of FGR cases followed the stage-based protocol for managing FGR [22]. Controls were selected among low-risk pregnancies with EFW and birth weight above the 10th centile and paired with cases by gestational age at scan (± 1 week). Gestational age at scan was calculated based on the crown-rump length obtained at first trimester scan. Structural/chromosomal abnormalities or cases with evidence of fetal infection were excluded. The local ethics committee approved the study protocol and all patients provided informed consent.

All women underwent ultrasound examination using a Voluson E8 (GE Medical Systems, Milwaukee, WI) that included estimation of fetal weight and standard fetoplacental Doppler evaluation in cases. At delivery, gestational age, birth weight, birth weight centile, mode of delivery, Apgar scores, presence of preeclampsia and admission to the neonatal intensive care unit were recorded.

Assessment of longitudinal annular displacement

LAD was assessed in all cases and controls with both the methods (online and offline STIC) from either an

apical or basal four-chamber view. For the online M-mode, insonation by the ultrasound beam was kept at an angle of <10 degrees to the orientation of the ventricular wall, with no angle correction applied. For measuring the extent of displacement between end-systole and end-diastole (as measured in mm), the maximum amplitude of motion was taken at the free wall of the left ventricle (mitral), right ventricle (tricuspid), and interventricular septum. Two well-trained operators performed the online measurements.

STIC volumes were acquired in all fetuses at the same time as the online M-mode measurement as previously described [11]. The acquisition time and angle used were 10 s, and 25 to 35 degrees, respectively, depending on the gestational age and the distance of the fetus from the transducer, preferably in an apical four-chamber view, avoiding maternal and fetal movements. STIC M-mode analysis was blindly performed by one experienced investigator. Offline, the operator adjusted the STIC volume by scrolling through the volume slices and adjusting X-, Y-, Z-axis, and contrast. LAD was measured in the same way as online, except for the angle of insonation. Due to the possibility of placing the M-mode arrow as preferred, the insonation angle was always parallel to the interventricular septum or the lateral walls [6]. In order to optimize the measuring conditions, the speed was adjusted to see three to five cardiac cycles and the Y-axis was maximized. On the thus obtained M-mode images, the maximum distance of the resulting waveform was measured (Figure 1). In the four-chamber view, we also measured cardiac size as cardiac long axis from apex to base.

Statistical analysis

Data were analyzed using IBM SPSS Statistics 19 (IBM Corporation, Armonk, NY). Sample size was calculated to enable us to observe a difference of 0.5 mm in LAD between FGR and controls, with 80% power, group A mean 7.2, group B mean 6.7, SD 1.1, two-sided, alpha 5% and power 80%. This leads to a minimum of 38 cases per study group. Comparison between study groups was performed by Student *T* test for independent samples and the Fisher's exact test where appropriate. The two methods of measurements were compared by Bland-Altman plot and Pearson's correlation. $p < .05$ was considered as statistically significant. In order to adjust for cardiac size, a subanalysis including 40 FGR cases and 40 controls paired by cardiac long axis dimension was also performed (Supplemental data).

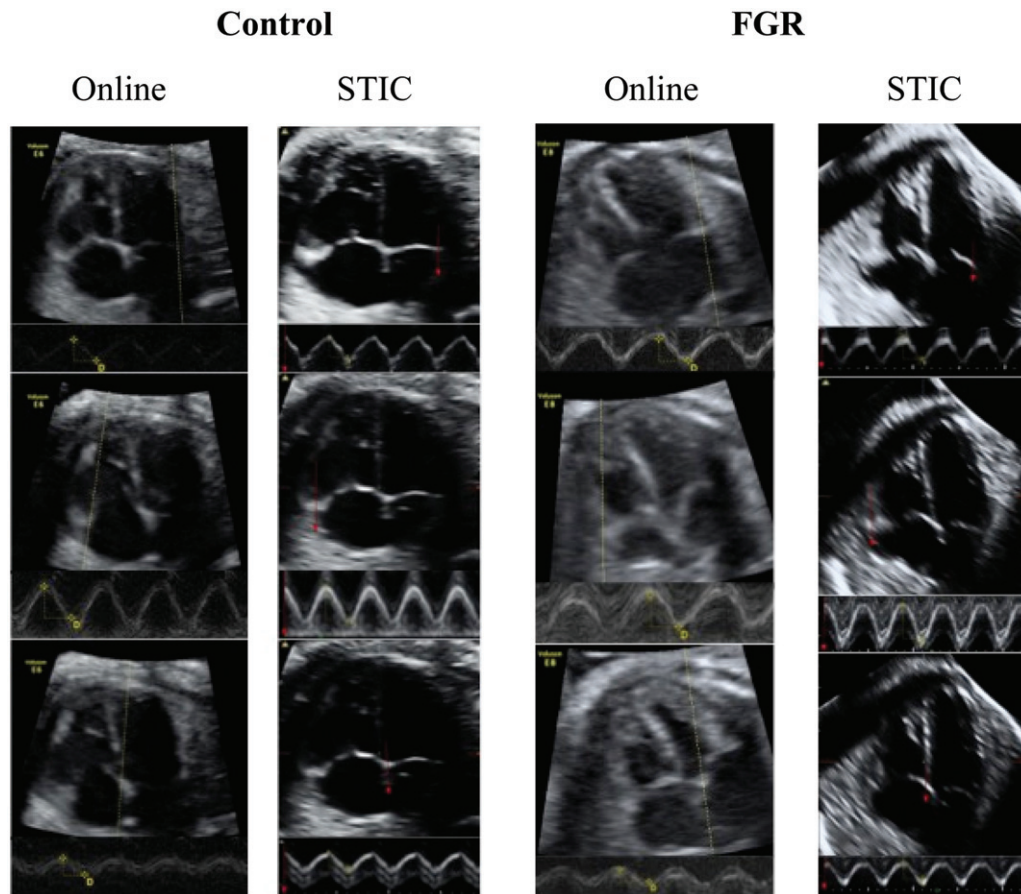


Figure 1. Examples of left (superior), right (middle), and septal (inferior) LAD measurements using online and STIC M-mode in a normally grown fetus (control) and case of fetal growth restriction (FGR).

Results

Study populations

Characteristics of the study populations are shown in Table 1. Baseline characteristics were similar in cases and controls regarding maternal data, gestational age at ultrasound, gender, umbilical artery and vein pH, and preeclampsia and cesarean section rate. As expected, FGR cases showed a lower estimated fetal weight, birth weight, birth weight centile, gestational age at birth, and Apgar score. In FGR cases, 27% had abnormal Doppler PI values (above 95th centile) of the mean uterine artery, 7% abnormal umbilical artery, 2% abnormal (below 5th centile) middle cerebral artery, 2% abnormal ductus venosus, 2% abnormal aortic isthmus. Gestational age range at ultrasound was 25.0–40.2 with a mean of 32.9 weeks.

Results on longitudinal annular displacement

Results on left, right, and septal LAD by online and STIC M-mode are shown in Figure 2 (and Table 1s supplemental data). Our first aim was to compare online and STIC M-mode. There was a non-significant trend

Table 1. Baseline characteristics and perinatal outcome in the study populations.

Characteristics	Controls <i>N</i> = 72	FGR <i>N</i> = 40	<i>p</i>
Maternal data			
Maternal age (years)	32.7 ± 5.5	32.3 ± 5.6	.586
Caucasian (<i>n</i> = 70/39)	52 (74)	28 (72)	.778
Smokers	8 (11)	5 (13)	.826
Fetoplacental US			
GA at US (weeks)	32.9 ± 3.0	32.8 ± 3.7	.901
EFW (g)	2124.3 ± 568.3	1604.9 ± 548.4	<.001
Pregnancy outcomes			
Preeclampsia (<i>n</i> = 64/37)	1 (2)	1 (8)	.104
GA at delivery (weeks)	39.9 ± 1.2	37.4 ± 3.4	<.001
Birth weight (g)	3465.9 ± 390.5	2253.1 ± 573.0	<.001
Birth weight centile	56.1 ± 27.2	3.3 ± 3.0	<.001
Cesarean section (<i>n</i> = 64/38)	15 (23)	14 (37)	.147
Gender (male)	39 (54)	21 (53)	.865
1 minute Apgar score	8.9 ± 0.8	8.2 ± 2.1	.048
5 minutes Apgar score	9.9 ± 0.4	9.2 ± 1.9	.008
UA pH	7.23 ± 0.08	7.25 ± 0.09	.297
UV pH	7.33 ± 0.07	7.31 ± 0.08	.081
Neonatal resuscitation (<i>n</i> = 62/36)	2 (3)	6 (17)	.019
NICU admission (<i>n</i> = 61/37)	3 (5)	8 (22)	.017

Data are given as mean ± SD or numbers (%). FGR: fetal growth restriction; GA: gestational age; US: ultrasound; EFW: estimated fetal weight; Ut: uterine artery; PI: pulsatility index; UA: umbilical artery; MCA: middle cerebral artery; UV: umbilical vein; NICU: neonatal intensive care unit.

for lower online M-mode LAD values in FGR as compared to controls. When paired by cardiac long axis dimension, we found a significant decrease in left LAD

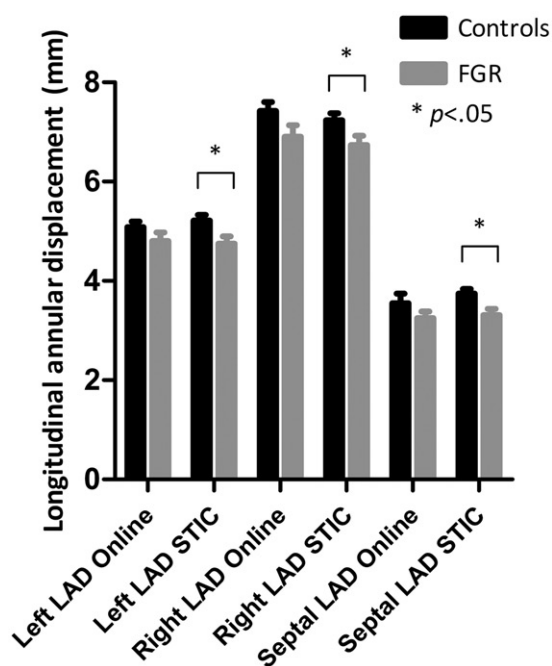


Figure 2. Results on left, right, and septal LAD using online and STIC M-mode comparing FGR cases and controls. Data are mean and standard error of the mean.

values by STIC and a non-significant trend to lower values in all the other LAD measurements (Table 2s Supplemental data). Pearson's correlation coefficients between online and STIC M-mode were .270 ($p = .004$) for left LAD, .386 ($p < .001$) for right LAD, and .130 ($p = .366$) for septal LAD. Bland-Altman plots are shown in Figure 1(s) supplemental data. Our second aim was to compare LAD in FGR cases with controls. LAD values by STIC were significantly decreased in the FGR group as compared to controls.

Discussion

This study indicates that STIC M-mode might be an alternative for online M-mode for detecting subtle changes in myocardial motion. The advantage of STIC is that it allows an ideal placement of the M-mode arrow. On the other hand, the advantage of online M-mode is its quick applicability. Altogether, STIC may improve conventional online M-mode in the detection of subtle differences in cardiac dysfunction. It further confirms previous data suggesting decreased LAD in FGR cases.

In this study, we assessed LAD with both online M-mode and STIC M-mode. Conventional online M-mode showed no significant differences between FGR and controls, whereas with STIC M-mode left, right, and septal LAD was significantly lower in the FGR group. Online M-mode offers the possibility of measuring LAD quickly during the ultrasound

assessment. However, due to fetal movement and position, the sonographer may often have difficulties with obtaining well-aligned images to measure LAD at an insonation angle of zero degrees. Therefore, the displacement may not be measured at its maximum and with higher variability so that differences between FGR and controls appear less prominent, even with the insonation angle kept $<30^\circ$. This disadvantage is minimized when LAD is measured using STIC. The offline software provides the possibility to place the M-mode cursor at any preferred position, always providing an insonation angle of zero degrees and therefore a more precise measure of LAD. This is in line with previous findings. Germanakis et al. demonstrated higher LAD values in anatomic M-mode when compared to online M-mode in healthy fetuses, suggesting this is due to the more easily achieved offline alignment of the M-mode cursor [3]. Therefore, if anatomic M-mode is present on a modern ultrasound machine, it can improve online measurements due to its possibility to adjust the M-mode angle. Messing et al. studied right LAD in healthy fetuses with STIC and online M-mode, and showed that both methods produce similar measures but STIC had a greater success rate [6]. In addition, Messing et al. found high interobserver correlations for both STIC and conventional M-mode in measuring right LAD [6]. Nevertheless, the disadvantage of STIC M-mode lies in the time it takes to do the offline analysis as well as a potentially lower temporal resolution. In conclusion, differences observed in our study suggest that STIC could be considered as an alternative for online M-mode in detecting subtle cardiac dysfunction. This might be due to the expected higher technical accuracy of STIC. STIC could, therefore, be helpful in monitoring fetuses with subtle cardiac dysfunction. Further studies are required to confirm our findings and determine the role of this technique in assessing fetal cardiac function.

We could demonstrate a significant reduction of LAD in the left, right, and septal wall in FGR cases, which is consistent with previous data suggesting decreased longitudinal motion in severe early growth-restricted fetuses [19]. We have previously demonstrated significant lower LAD measured with online M-mode in severe IUGR cases born before a gestational age of 34 weeks, thus being early-onset and with an abnormal umbilical artery Doppler pulsatility index [19]. Therefore, that population contained more severe FGR cases as compared to the present study (including mainly late-onset cases with normal fetoplacental Doppler). These group differences may explain the non-significant trend in online M-mode in the present study. The present study is the first report

demonstrating significant changes in LAD in non-severe FGR by using STIC M-mode. Since both displacement and velocity relate to longitudinal motion, our findings are complementary with previous studies demonstrating lower E' and A' annular peak velocities by tissue Doppler in late-onset small-for-gestational age fetuses as compared to the controls [19,23,24].

We acknowledge that this study has several strengths and limitations. We took great care in data acquisition; online M-mode and 4D STIC loop acquisition took place in direct consecutive order. One experienced investigator performed STIC M-mode offline analysis, blinded for cases or controls. Therefore, unfortunately, we could not assess inter-observer variability. In addition, we did not perform intra-observer variability, since this was well established in previous literature. Another limitation is that our sample size prevents us to subdivide FGR cases according to Doppler findings. The limited sample size may partially explain the non-significant trend in the online M-mode results. Our study population was paired by gestational age at scan in order to adjust for maturational changes throughout gestation in cardiac function parameters. However, we acknowledge that longitudinal axis motion is also strongly related to cardiac size. In order to adjust for that, a sub analysis including cases and controls paired by cardiac size was also performed (Supplemental data), which lead to similar conclusions; a significant decrease in left LAD values by STIC and also a non-significant trend to lower values in all the other LAD measurements. Future studies are warranted to confirm our results and further validate the use of STIC M mode in the detection of early changes in cardiac function.

Conclusions

These data support the hypothesis that STIC could be helpful to monitor fetal cardiac condition *in utero* and it may improve conventional online M-mode in the detection of subtle differences in cardiac dysfunction. Reduced right LAD has been proposed as a predictive marker for postnatal hypertension and arterial remodeling in FGR [25]. We speculate that measuring LAD might be of use for the prenatal detection of those FGR cases at higher cardiovascular risk and that might benefit from postnatal interventions in order to potentially improve their future cardiovascular health.

Acknowledgements

This study was supported by grants from the Graduate School of Medical Sciences of the University of Groningen,

the research institute BCN-BRAIN, the Ministerio de Economía y Competitividad (ref. SAF2012-37196), the Instituto de Salud Carlos III (ref. PI11/00051, PI11/01709, PI12/02230) integrado en el Plan Nacional de I + D + I y cofinanciado por el ISCIII-Subdirección General de Evaluación y el Fondo Europeo de Desarrollo Regional (FEDER) "Otra manera de hacer Europa", the Cerebra Foundation for the Brain Injured Child (Carmarthen, Wales, UK), Obra Social "la Caixa", the Fundación Mutua Madrileña, and AGAUR 2014 SGR grant no. 928.

Disclosure statement

None of the authors has any conflict of interest to disclose.

References

- [1] Carvalho JS, O'Sullivan C, Shinebourne EA, et al. Right and left ventricular long-axis function in the fetus using angular M-mode. *Ultrasound Obstet Gynecol.* 2001;18:619-622.
- [2] Gardiner HM, Pasquini L, Wolfenden J, et al. Myocardial tissue Doppler and long axis function in the fetal heart. *Int J Cardiol.* 2006;113:39-47.
- [3] Germanakis I, Pepes S, Sifakis S, et al. Fetal longitudinal myocardial function assessment by anatomic M-mode. *Fetal Diagn Ther.* 2012;32:65-71.
- [4] Godfrey ME, Messing B, Valsky DV, et al. Fetal cardiac function: M-mode and 4D spatiotemporal image correlation. *Fetal Diagn Ther.* 2012;32:17-21.
- [5] Jurgens J, Chaoui R. Three-dimensional multiplanar time-motion ultrasound or anatomical M-mode of the fetal heart: a new technique in fetal echocardiography. *Ultrasound Obstet Gynecol.* 2003;21:119-123.
- [6] Messing B, Gilboa Y, Lipschuetz M, et al. Fetal tricuspid annular plane systolic excursion (f-TAPSE): evaluation of fetal right heart systolic function with conventional M-mode ultrasound and spatiotemporal image correlation (STIC) M-mode. *Ultrasound Obstet Gynecol.* 2013;42:182-188.
- [7] Bazaz R, Edelman K, Gulyasy B, et al. Evidence of robust coupling of atrioventricular mechanical function of the right side of the heart: insights from M-mode analysis of annular motion. *Echocardiography.* 2008;25:557-561.
- [8] Ghio S, Recusani F, Klersy C, et al. Prognostic usefulness of the tricuspid annular plane systolic excursion in patients with congestive heart failure secondary to idiopathic or ischemic dilated cardiomyopathy. *Am J Cardiol.* 2000;85:837-842.
- [9] Koestenberger M, Nagel B, Ravekes W, et al. Systolic right ventricular function in preterm and term neonates: reference values of the tricuspid annular plane systolic excursion (TAPSE) in 258 patients and calculation of Z-score values. *Neonatology.* 2011;100:85-92.
- [10] Hu K, Liu D, Herrmann S, et al. Clinical implication of mitral annular plane systolic excursion for patients with cardiovascular disease. *Eur Heart J Cardiovasc Imaging.* 2013;14:205-212.
- [11] DeVore GR, Falkensammer P, Sklansky MS, et al. Spatio-temporal image correlation (STIC): new

- technology for evaluation of the fetal heart. *Ultrasound Obstet Gynecol.* 2003;22:380–387.
- [12] Goncalves LF, Lee W, Espinoza J, et al. Examination of the fetal heart by four-dimensional (4D) ultrasound with spatio-temporal image correlation (STIC). *Ultrasound Obstet Gynecol.* 2006;27:336–348.
- [13] Yagel S, Cohen SM, Shapiro I, et al. 3D and 4D ultrasound in fetal cardiac scanning: a new look at the fetal heart. *Ultrasound Obstet Gynecol.* 2007;29:81–95.
- [14] Hecher K, Campbell S, Doyle P, et al. Assessment of fetal compromise by Doppler ultrasound investigation of the fetal circulation. Arterial, intracardiac, and venous blood flow velocity studies. *Circulation.* 1995;91:129–138.
- [15] Makikallio K, Vuolteenaho O, Jouppila P, et al. Ultrasonographic and biochemical markers of human fetal cardiac dysfunction in placental insufficiency. *Circulation.* 2002;105:2058–2063.
- [16] Leipala JA, Boldt T, Turpeinen U, et al. Cardiac hypertrophy and altered hemodynamic adaptation in growth-restricted preterm infants. *Pediatr Res.* 2003;53:989–993.
- [17] Crispi F, Bijmens B, Figueras F, et al. Fetal growth restriction results in remodeled and less efficient hearts in children. *Circulation.* 2010;121:2427–2436.
- [18] Demicheva E, Crispi F. Long-term follow-up of intra-uterine growth restriction: cardiovascular disorders. *Fetal Diagn Ther.* 2014;36:143–153.
- [19] Cruz-Lemini M, Crispi F, Valenzuela-Alcaraz B, et al. Value of annular M-mode displacement vs tissue Doppler velocities to assess cardiac function in intra-uterine growth restriction. *Ultrasound Obstet Gynecol.* 2013;42:175–181.
- [20] Crispi F, Bijmens B, Sepulveda-Swatson E, et al. Postsystolic shortening by myocardial deformation imaging as a sign of cardiac adaptation to pressure overload in fetal growth restriction. *Circ Cardiovasc Imaging.* 2014;7:781–787.
- [21] Figueras F, Meler E, Iraola A, et al. Customized birthweight standards for a Spanish population. *Eur J Obstet Gynecol Reprod Biol.* 2008;136:20–24.
- [22] Figueras F, Gratacos E. Update on the diagnosis and classification of fetal growth restriction and proposal of a stage-based management protocol. *Fetal Diagn Ther.* 2014;36:86–98.
- [23] Larsen LU, Petersen OB, Sloth E, et al. Color Doppler myocardial imaging demonstrates reduced diastolic tissue velocity in growth retarded fetuses with flow redistribution. *Eur J Obstet Gynecol Reprod Biol.* 2011;155:140–145.
- [24] Comas M, Crispi F, Cruz-Martinez R, et al. Tissue Doppler echocardiographic markers of cardiac dysfunction in small-for-gestational age fetuses. *Am J Obstet Gynecol.* 2011;205:57.e1–57.e6.
- [25] Cruz-Lemini M, Crispi F, Valenzuela-Alcaraz B, et al. A fetal cardiovascular score to predict infant hypertension and arterial remodeling in intrauterine growth restriction. *Am J Obstet Gynecol.* 2014;210:552.e1–552.e22.